

DR PAUL ENOCHS M.D., BARIATRIC SURGEON, NORTH CAROLINA, USA

Robotic Single Incision Sleeve Gastrectomy using the LiVac® Retractor System



Case Presentation

28-year-old female

BMI: 42

Patient preference for no visible scarring

Procedure

SILS sleeve gastrectomy (robotic)

Set up

Da Vinci Xi® surgical system

Liver retraction using a 56mm LiVac Retractor

In this case, the LiVac was chosen as it:

- Can be inserted via the existing single surgical incision
- Doesn't clash with the robot arm or interfere with electronic equipment
- Sits entirely outside the surgical field
- Provides reliable retraction throughout the procedure
- Does not require an additional incision, minimizing patient scarring.

In this case, the LiVac Retractor system:

- Was inserted alongside the SILS port, enabling single-incision, minimally invasive surgery
- Eliminated the need for a painful, epigastric incision
- Did not clash or interfere with the robot arms
- Provided retraction of the left liver lobe outside the surgeon's field of view exposing the upper gastric area for the duration of the procedure.

The patient was reportedly satisfied with the single incision approach and the cosmetic result.

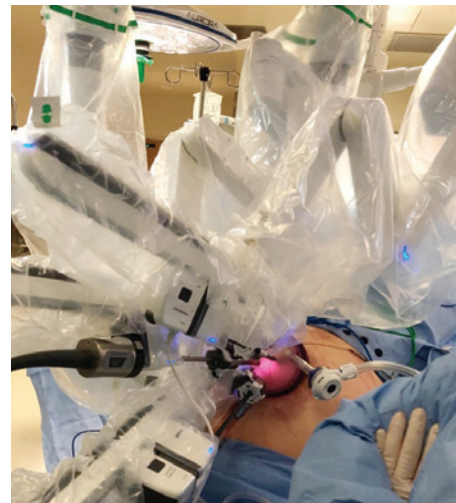

Figure 1 – SILS Da Vinci Xi set up

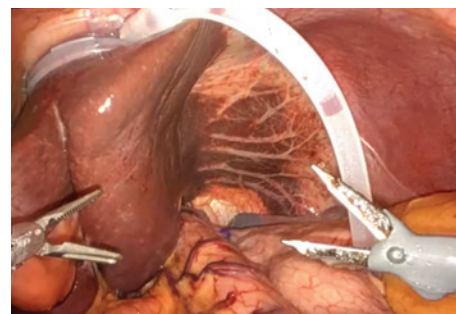


Figure 2 – The LiVac in position between the liver and the diaphragm

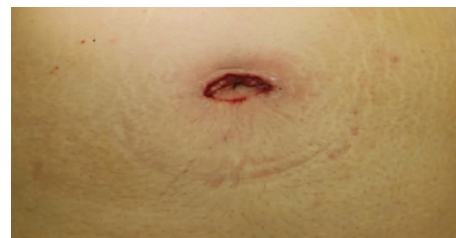

Figure 3 – Immediately post-procedure

For more information on the LiVac Retractor system, please contact your representative or go to livac.com

Livac USA One Life Sciences, Inc. ("KURO"),
4976 Highway 169 N, Minneapolis MN 55428 USA
Contact +1 612 467 9186 or customerservice@livac-usa.com livac.com

Livac is a trade mark of Livac Pty Ltd

Da Vinci Xi ® is a registered trademark of Intuitive™

